



## Case Report

## The Study of the Effect of Neuromuscular Electrical Stimulation Therapy in Children with Absent Gag Reflex: A Case Study

Shiva Ebrahimian<sup>1,2</sup>, PhD; Maryam Ebrahimian<sup>2,3\*</sup>, PhD; Fateme Mohammadianfar<sup>1</sup>, BSc

<sup>1</sup>Department of Speech Therapy, School of Rehabilitation Sciences, Shiraz University of Medical Sciences, Shiraz, Iran

<sup>2</sup>Rehabilitation Sciences Research Center, Shiraz University of Medical Sciences, Shiraz, Iran

<sup>3</sup>Department of Physical Therapy, School of Rehabilitation Sciences, Shiraz University of Medical Sciences, Shiraz, Iran

### ARTICLE INFO

#### Article History:

Received: 16/10/2019

Revised: 03/03/2020

Accepted: 10/03/2020

#### Keywords:

Dysphagia

Electrical stimulation

Gag reflex

Please cite this article as:

Ebrahimian S, Ebrahimian M, Mohammadianfar F. The Study of the Effect of Neuromuscular Electrical Stimulation Therapy in Children with Absent Gag Reflex: A Case Study. *JRSR*. 2020;7(1):43-46.

### ABSTRACT

Research shows that 1% of children experience swallowing difficulties, though the incidence is higher in some, such as those with cerebral palsy and brain injury. One of the causes of pharyngeal phase dysphagia is the absent gag reflex. The aim of this case study was to investigate the effects of sensory stimulation combined with Neuro Muscular Electrical Stimulation (NMES) on dysphagia and gag reflex.

This study was conducted on a 2.5-year-old child with midbrain disorders and absence of oral swallowing and gag reflex. At the beginning of the treatment, sensory-tactile stimulation were provided which induced successful oral swallowing. The treatment was then continued with NMES along with stimulations of the sensory-tactile receptor. Over 26 sessions of NMES, the gag reflex was induced by a 2-second stimulation of the posterior pharyngeal wall, and the time interval between suction increased to two hours. The present study showed that NMES activates and strengthens the muscles involved in swallowing.

2020© The Authors. Published by JRSR. All rights reserved.

### Introduction

Research shows that approximately 1% of children experience swallowing difficulties, though the incidence is higher in some, such as those with cerebral palsy and brain injury [1]. This disorder changes the quality of life and causes problems for affected individuals. It also imposes heavy costs on the community of health system [2]. Any disorder in the movement of a mass of food from the mouth to the stomach, which decreases safety or nutritional adequacy of the food, is known as dysphagia [1]. A swallowing disorder consists of several stages, including oral, pharyngeal, and esophageal [3]. One of the causes of pharyngeal phase dysfunction is the absent gag reflex [4, 5]

Sensory stimulation therapy was first developed and

practiced by Castillo Morales. Sensory stimulation is based on sensory-motor reflex arcs. This method mainly involves various forms of direct manipulation and stimulation of muscles and sensory areas [6].

Moreover, neuromuscular electrical stimulation is also used in the treatment of dysphagia. This treatment method produces muscle contraction and improves muscle activity through electrical stimulation of muscles and receiving sensory inputs [7]. There are still cases of disagreements in scientific texts concerning the efficacy of this method compared to traditional ones [8]. Studies have demonstrated that neuromuscular electrical stimulation is an effective treatment for stroke-induced dysphagia and Parkinson's patients with oropharyngeal dysphagia, enhancing their quality of life [9-11].

For the purposes of the study, several searches were made on Google Scholar and PubMed during summer 2018, with keywords such as dysphagia, swallowing in children, absent gag reflex, pharyngeal dysphagia, oropharyngeal dysphagia, sensory and passive motor

\*Corresponding author: Maryam Ebrahimian, Department of Physical Therapy, School of Rehabilitation, Abiverdil st- Chamran avn- Shiraz, Iran. Tel: +98 71 36271552; Email: [ebrahimian@sums.ac.ir](mailto:ebrahimian@sums.ac.ir)

stimulation, thermal stimulation, and neuromuscular electrical stimulation in children and adults in Persian and English. The studies and searches done during the mentioned time period revealed that a few articles were available on the research topic (Table 1), indicating the limited studies conducted on the use of neuromuscular electrical stimulation in the treatment of dysphagia in children [12-14].

Several studies have reported that neuromuscular electrical stimulation is an effective method to treat children with dysphagia and chronic aspiration [15, 16]. Some others, however, have found no significant difference in the dysphagia scores of affected children before and after treatment. Besides, the effect of sensory and passive motor stimulation and neuromuscular electrical stimulation has been individually investigated and compared in previous studies [17], and no study has examined the combined effect of these two methods.

Therefore, the present case study aimed to investigate the effect of sensory and passive motor stimulation combined with neuromuscular electrical stimulation on the occurrence of gag reflex and treatment of dysphagia in a child with a brainstem lesion.

## Case Report

This study was conducted on a 2.5-year-old boy with midbrain disorders. The boy was born at 36 weeks of gestation, and was admitted to the neonatal intensive care unit at birth for 10 days. He received hydrocephalus

treatment at two months and was fed orally for the first six months. Subsequently, the feeding was done via a nasogastric tube for three months due to severe pneumonia, and via a PEG tube from 9 months of age till now.

Sagittal MRI of the midbrain shows evidence of chiari malformation (foramen magnum stenosis, downward displacement of cerebellum and torcula, and two syrinx in the cervical spinal cord and craniocervical junction), which can cause swallowing and speech problems (Figures 1 and 2).

Prior to treatment, the child lacked oral swallowing (even saliva) and gag reflex, and required suction every 4 minutes on average, and developed cyanosis in the absence of suction (cough without coughing). He also had severe speech delay and even lacked nonverbal vocalization [3].

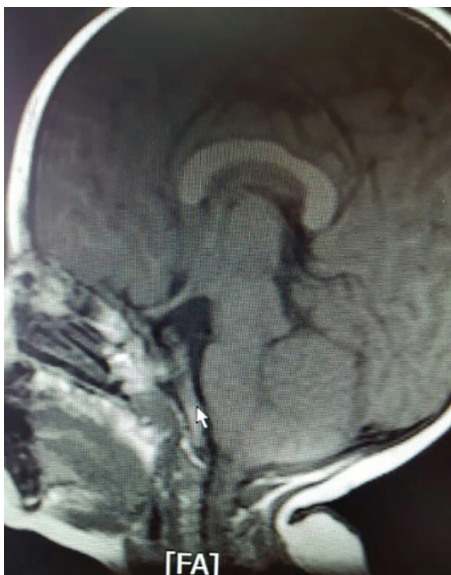
The child has been receiving treatment for dysphagia and absent gag reflex since March 2018. Before beginning each treatment method, the necessary explanations were provided to the child's family and a written consent was obtained. Then, sensory stimulation therapy, including tactile, pressure, and thermal stimulation was applied to the gums, lips, tongue, soft palate and cheeks. The sensory and passive motor stimulation was applied with gradually greater depth and intensity. The sensory stimulation was continued for four months.

Sensory and passive motor stimulation was applied once a day, from March to July 2018, as follows:

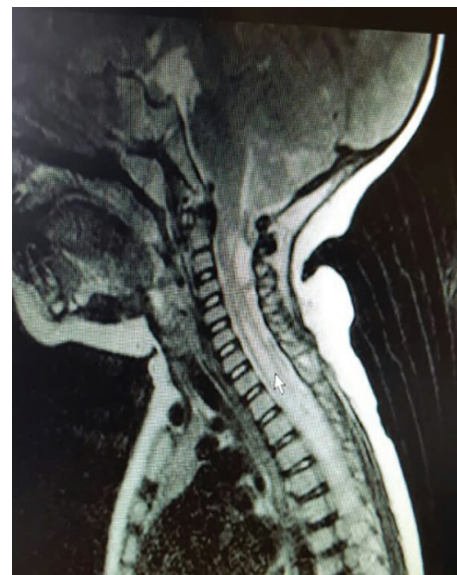- Manual contact of the red part of the upper and lower

**Table 1:** The list of articles that were found

Headline	Author and year of publication
Effects of Neuromuscular Electrical Stimulation on Swallowing Functions in Children with Cerebral Palsy: A Pilot Randomised Controlled Trial	Woo Jin Song , Ji Hyuk Park , Joo Hyun Lee , Min Young Kim 2015
Neuromuscular Electrical Stimulation in the Early Intervention Population: A Series of Case Studies	Kelly L. Rice 2012
Neuromuscular Electrical Stimulation is No More Effective Than Usual Care for the Treatment of Primary Dysphagia in Children	Mary E. Christiaanse, Betty Mabe, Greg Russell, Tanya Long Simeone, John Fortunato, and Bruce Rubin 2011
Neuromuscular Electrical Stimulation in Dysphagia Management: Clinician Use and Perceived Barriers	Samantha Shune, Jerald B. Moon 2012



**Figure 1:** There is evidence of narrowing of the foramen magnum and downward displacement of the cerebellum and torcula as well as the crowding of the posterior fossa

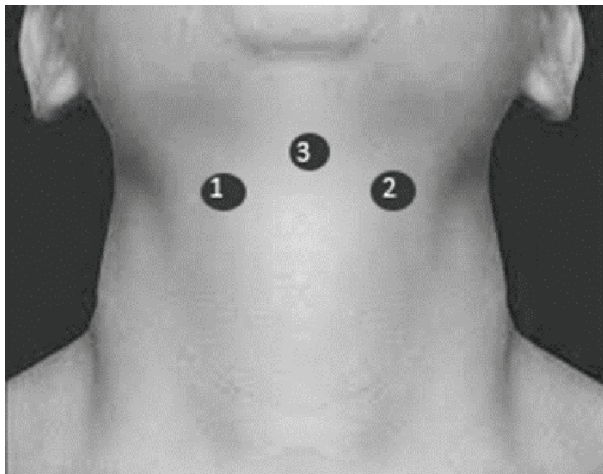


**Figure 2:** In the cervical cord, there is evidence of an elongated syrinx form the vertebral body of C7

lips from left to right with a tongue depressor, each lip 60 seconds

- Manual contact of the vestibule of lips from left to right with a tongue depressor, each one 60 seconds
- Manual contact of the tongue surface from back to front with a tongue depressor, for 60 seconds
- Manual contact of the palate from back to front with a tongue depressor, for 60 seconds
- Manual contact of the right and left inner cheeks, from inside out, with a tongue depressor, each cheek 60 seconds
- posterior soft palate pressure with a finger and passive holding for a second, once a day, for the first month; and twice a day from the second month to July 2018
- Gentle random taps on the suprahyoid area with four fingers, two times a day, each time 20 seconds
- Massage of the anterior belly of digastric with the index finger for repeated contraction, each side 20 seconds, up to two times in a day
- Instantaneous and point thermal stimulation of the posterior wall of the pharynx, three times a day, each time 20 points, for the first month; and each time 30 points from the second month to July 2018
- Taste stimulation of posterior of the tongue with a tongue depressor coated with coffee, three times a day, each time 10 seconds, for the first two weeks; three times a day, each time 20 seconds, for the second two weeks; and three times a day, each time 25 seconds from the fifth week to July 2018
- Passive elevation of the soft palate with the index finger, once a day, repeated 20 times, for the first three weeks; and twice a day, repeated 40 times, from then to July 2018
- Passive depreton of the root of the tongue with the index finger, four times a day

At the end of four months of treatment with sensory and passive motor stimulation, neuromuscular electrical stimulation was added with the aim of retraining and strengthening the muscles of the pharynx and suprahyoid area. Neuromuscular electrical stimulation was applied with 70-80  $\mu$ s duration (due to muscle innervate), 20 Hz frequency (due to the delicacy of the muscles), 3-30 mA intensity (to the extent that muscle contraction occurs).



**Figure 3:** NMES used in three areas in the front of the neck (the middle and two lateral points on the suprahyoid region) [19]

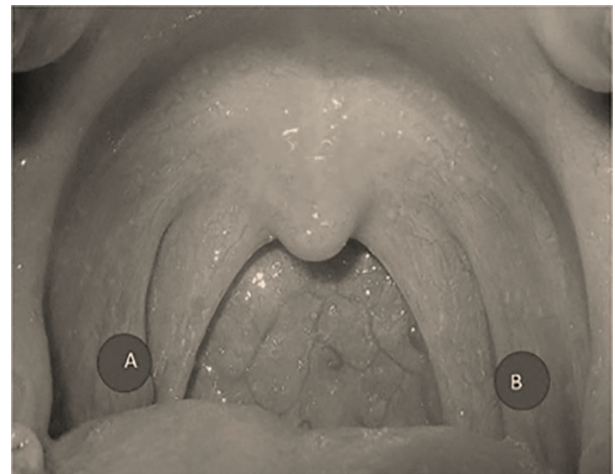
Each muscle received 60 stimulations per session. The intensity of electrical stimulation applied to the pharyngeal region was less than that of the suprahyoid area [18]. These stimulations were used in three areas in the front of the neck (the middle and two lateral points on the suprahyoid region) (Figure 3) and the pharyngeal region (two points on the right and left sides) (Figure 4). These stimulations administered for twenty six 30-45 minutes sessions over a period of nine months. The minimum interval between sessions was one day, and the maximum was four weeks due to the child's recurrent pneumonia.

## Discussion

By receiving sensory and passive motor stimulation, the child achieved saliva swallowing, as well as 10 cc of water and 3-5 cc of fruit juice. The interval between suctions increased to 10 minutes, but there was still no response to the gag reflex. Regarding speech and language skills, vocalization increased, and the child developed the ability to produce vowels, nasal consonants, and five expressive words.

By adding neuromuscular electrical stimulation to sensory and passive motor stimulation, and after completing 26 sessions of treatment over 9 months, the child manage to orally swallow 110 cc of liquids (70 cc of water and 40 cc of carrot juice) and ten teaspoons of semi-solid. The interval between two suctions increased to 2 hours. Also, the gag reflex response was triggered by a 2-second stimulation of the posterior pharyngeal wall, and the child did not develop cyanosis any longer.

The mechanism involved in the effect of neuromuscular electrical stimulation on muscle strength is still unknown. Two theories have been put forward to explain this mechanism. One theory suggests that the improvement in muscle strength during neuromuscular electrical stimulation is similar to voluntary movements. Therefore, neuromuscular electrical stimulation protocols that target muscle strength should include a low repetition strong muscle contraction. In the present study, the intensity of stimulation was regulated in such a way that it induced contraction in the pharyngeal and



**Figure 4:** NMES used in the pharyngeal region (two points on the right and left sides) [20]



suprahyoid muscles and 60 stimulations were applied for each muscle per session. The other theory is based on type II (fast twitch) muscle recruitment. Neuromuscular electrical stimulation first stimulates the type II muscle. The pharyngeal and suprahyoid muscles are of this type.

The results of this case study suggests that sensory and passive motor stimulations combined with neuromuscular electrical stimulations is an effective intervention for cerebral palsy children with pharyngeal dysphagia and absent gag reflex.

The neuromuscular electrical stimulation used to treat the movement system utilizes a low-voltage electric current to muscle tissue to induce contraction. The observed neuromuscular response is affected by the characteristics of the electric current; for example, higher frequencies of stimulation induce more intense muscular contractions but also can fatigue muscles quickly, while lower frequencies produce lower muscle forces, but significantly reduce fatigue [21].

Studies have suggested electrical stimulation therapy for the neuromuscular system with central nervous system disorders. The neuromuscular response is affected by several factors, such as the characteristics of the electrical current (continuous or alternating), electrode placement method, the length of a treatment session, the application of stimulation at rest, or during functional activities, etc. But In general, there is limited information on the use of appropriate electrical stimulation parameters in providing high or low strengths of contractions for various muscle groups involved in swallowing [22]. Because the child in question had serious limitations in receiving regular treatment due to recurrent pneumonia, and in light of the discrepancies among references on the effect of neuromuscular electrical stimulation on pharyngeal dysphagia in children, and also because of the lack of studies on the effect of sensory and passive motor stimulation combined with neuromuscular electrical stimulation, the author suggests that clinical trials investigate the effect of neuromuscular electrical stimulation on the pharyngeal dysphagia in children as well as various factors affecting neuromuscular responses.

**Conflict of Interest:** None declared.

## References

1. Dodrill P, Gosa MM. Pediatric Dysphagia: Physiology, Assessment, and Management. *Ann Nutr Metab.* 2015;66 (Suppl 5):24-31.
2. Pownall S, Enderby P, Sproson L. Electrical stimulation for the treatment of dysphagia. *Electroceuticals: Springer;* 2017; p. 137-156
3. Rosenbek JC, Jones HN. *Dysphagia in movement disorders: Plural Publishing;* 2008.
4. Leder SB. Gag reflex and dysphagia. *Head & neck.* 1996;18(2):138-41.
5. Daniels SK. Neurological disorders affecting oral, pharyngeal swallowing. *GI Motility online* , 2006, doi:10.1038/gimo34
6. Hägg M, Larsson B. Effects of motor and sensory stimulation in stroke patients with long-lasting dysphagia. *Dysphagia.* 2004;19(4):219-30.
7. Oh DH, Park JS, Kim WJ. Effect of neuromuscular electrical stimulation on lip strength and closure function in patients with dysphagia after stroke. *J Phys Ther Sci.* 2017;29(11):1974-5.
8. Ludlow CL. Electrical neuromuscular stimulation in dysphagia: current status. *Curr Opin Otolaryngol Head Neck Surg.* 2010;18(3):159-64.
9. Permsirivanich W, Tipchatyotin S, Wongchai M, Leelamanit V, Sethawatcharawanich S, Sathirapanya P, et al. Comparing the effects of rehabilitation swallowing therapy vs. neuromuscular electrical stimulation therapy among stroke patients with persistent pharyngeal dysphagia: a randomized controlled study. *J Med Assoc Thai.* 2009;92(2):259-65.
10. Ludlow CL. Electrical neuromuscular stimulation in dysphagia: current status. *Curr Opin Otolaryngol Head Neck Surg.* 2010;18(3):159-64.
11. Heijnen BJ, Speyer R, Baijens LW, Bogaardt HC. Neuromuscular electrical stimulation versus traditional therapy in patients with Parkinson's disease and oropharyngeal dysphagia: effects on quality of life. *Dysphagi* 2012.; 27(3) : 336-45
12. Miller CK, Willging JP. Advances in the evaluation and management of pediatric dysphagia. *Curr Opin Otolaryngol Head Neck Surg.* 2003;11(6):442-6.
13. Arvedson J. Feeding children with cerebral palsy and swallowing difficulties. *Eur J Clin Nutr.* 2013;67(S2):S9.
14. Christiaanse ME, Mabe B, Russell G, Simeone TL, Fortunato J, Rubin B. Neuromuscular electrical stimulation is no more effective than usual care for the treatment of primary dysphagia in children. *Pediatric pulmonology.* 2011;46(6):559-65.
15. Rice KL. Neuromuscular electrical stimulation in the early intervention population: A series of five case studies. *Internet J Allied Health Sci Pract.* 2012;10(3):9.
16. Song WJ, Park JH, Lee JH, Kim MY. Effects of neuromuscular electrical stimulation on swallowing functions in children with cerebral palsy: a pilot randomised controlled trial. *Hong Kong J Occup Ther.* 2015;25:1-6.
17. Freed ML FL, Chatburn RL, M C. Electrical stimulation for swallowing disorders caused by stroke. *Respir Care.* 2001;46:466-74.
18. Robertson V. WA, Low J., Reed A. *Electrotherapy Explained (principles and practice).* 4th. ed2006. P 126-30.
19. *VitalStim Therapy Training Manual – Electrode Placement Abstract* © Copyright Yorick Wijting, and Marcy Freed, M.A. ; p 4.
20. In: <https://upload.wikimedia.org /Dake . Pharyngitis.jpg> ; 2016.
21. Clark HM. Neuromuscular treatments for speech and swallowing: a tutorial. *Am J Speech Lang Pathol.* 2003;12(4):400-15.
22. Cichero JA, Murdoch BE. *Dysphagia: foundation, theory and practice: John Wiley & Sons;* 2006, p 375.